CHAPTER

37 The spine

Learning objectives

To learn:

- The salient features relating to the history and examination of the spine
- The investigations commonly used in the field of spinal disorders
- The treatment principles for common conditions affecting the spine
- The global issues in spinal surgery

EPIDEMIOLOGY

The lifetime prevalence of low back pain has been reported to be 60–80%. By contrast, the lifetime prevalence of true sciatica is 2–4%. It is generally accepted that 90% of acute low back pain episodes settle, allowing return to work within 6 weeks. However, some 5–7% of the population aged between 45 and 64 years will report back problems as a 'chronic sickness'. Up to 70% of acute episodes of sciatica resolve within 3 months.

Summary box 37.1

Epidemiology

- Low back pain is extremely common
- 90% of acute low back pain episodes settle within 6 weeks
- Sciatica is much less frequent
- 70% of acute sciatic episodes settle within 3 months

CLINICAL ANATOMY

The normal cervical lordosis measures between 35° and 45°. The normal lumbar lordosis is between 40° and 80° (mean 60°) and decreases with age. Most lumbar lordosis occurs between L4 and S1. The normal thoracic kyphosis is between 20° and 50° (mean 35°) and increases with age. When standing, the normal sagittal vertical axis (sagittal plumb line) falls from the odontoid process through the C7/T1 disc space and crosses the spinal column at the T12/L1 disc space, before reaching the posterosuperior corner of the S1 vertebral body. For an energy-efficient posture, cervical and lumbar lordosis will balance thoracic kyphosis.

The spinal canal is formed behind the articulated vertebral body by the posterior elements of the vertebral column and can be divided into a **central** portion and two **lateral** portions. The central portion is occupied by the thecal sac containing the spinal cord, which terminates behind the body of L1. The lateral portions contain the nerve roots.

The spinal nerve roots comprise 8 cervical, 12 thoracic, 5 lumbar, 5 sacral and 1 coccygeal. Dorsal and ventral roots join to form spinal nerves. The ventral root and the dorsal root ganglion lie within the intervertebral foramen. This foramen is bounded superiorly and inferiorly by pedicles, anteriorly by the disc and posteriorly by the facet joint. Degenerative changes in these structures may lead to neural compromise. Laminar overlap within the lumbar spine decreases from L1 to S1 so that, at the L5/S1 level, access to the intervertebral disc requires less bone removal than at a more proximal level.

The blood supply of the spinal cord is derived from the vertebral, deep cervical, intercostal and lumbar arteries. The arteries of the spinal cord include the anterior spinal artery and two posterior spinal arteries, with the anterior spinal artery providing the majority of the vascular supply to the spinal cord. The radicular artery of Adamkiewicz makes a major contribution to the anterior spinal artery, supplying the lower spinal cord. It originates on the left in 80% of people, usually accompanying the ventral root of T9, T10 or T11, but can originate anywhere from T5 to L5. Ligation of this important artery may lead to critical ischaemia of the spinal cord. Ligating segmental vessels over the midpoint of the vertebral body will minimise the risk of injury to this important artery during anterior approaches to the spine.

PATIENT HISTORY

The commonest reasons for referral to a spinal clinic include **pain** and **spinal deformity**. A detailed history of the pain, including site, type, severity, duration, frequency and aggravating factors, should be sought. Has there been any history of

Albert Adamkiewicz, 1850–1921, Professor of Pathology, the University of Kraków (Cracow), Poland, described the arterial supply to the spinal cord in 1882.

trauma? Is the pain present at night? Is there associated pain in the upper limbs (brachialgia) or lower limbs (sciatica)? Is there associated numbness, tingling, weakness or difficulty with gait? Is there a family history of ankylosing spondylitis or rheumatoid arthritis? Are there concurrent medical conditions such as diabetes, peripheral vascular diseases, osteoarthritis of the hip or previous malignancies? Are there systemic symptoms such as unexplained weight loss, chills or fever?

Patients should always be asked about the presence of perineal numbness (saddle area) and difficulties or changes in sensation when passing urine or faeces, as these symptoms may indicate a cauda equina syndrome (CES) (*Table 37.1*).

Patients should be asked whether the pain is interfering with their ability to work. What treatment has the patient already tried and how effective were these treatments (e.g. analgesics, exercise, physiotherapy or spinal injections)? Pending litigation or worker's compensation claims may have a negative prognostic effect on future treatments.

Spinal deformities, e.g. scoliosis and excessive kyphosis (>50°), are generally painless in children but may be symptomatic in adult life. How quickly has the spinal deformity progressed? It is important to assess skeletal maturity and whether the child has gone through a recent growth spurt. Has menstruation commenced in the female or has the voice dropped in the male, indicating the onset of puberty?

TABLE 37.1 Cauda equina syndrome

- Low back pain
- Uni- or bilateral sciatica
- Saddle anaesthesia
- Motor weakness in the lower extremities
- Variable rectal and urinary symptoms

PHYSICAL EXAMINATION

The patient should be undressed and posture should be evaluated in both frontal and sagittal planes. Shoulder or waist asymmetry suggests the presence of scoliosis. The Adams forward bend test will accentuate trunk asymmetry and allow appreciation of rib or loin prominence on the convex side of each curve. The skin should be examined for cutaneous neurofibromata, café-au-lait patches or axillary freckling commonly present in neurofibromatosis. Neurological examination should include abdominal reflexes. Leg lengths should be measured. In the case of kyphosis, the sagittal alignment and forward gaze should be assessed.

Palpation is useful to locate specific areas of tenderness. The normal range of motion in the cervical spine is 45° of flexion, 55° of extension, 70° of rotation and 40° of lateral bend. The normal range of motion in the lumbar spine is 40–60° of flexion, 20–35° of extension, 15–20° of lateral bending and 3–18° of rotation. Schober's test is a simple clinical test to evaluate spinal mobility. A tape measure is used to mark the skin midway between the posterior superior iliac spines and at points 10 cm proximal and 5 cm distal to this mark while the patient is standing. The patient is then asked to bend forwards as far as possible and the distance between the two points is measured with the patient in the flexed position. Normally one would expect to see an increase of at least 5 cm between the two points in the erect and flexed positions. A distance of less than 5 cm between these points may indicate ankylosing spondylitis.

Neurological examination of the upper and lower limbs will focus on tone, power, coordination, reflexes, sensation and gait (*Tables 37.2 and 37.3*). A rectal examination and assessment of perineal sensation should be performed if there is any concern about cauda equina integrity. The superficial abdominal reflex is an upper motor neurone (UMN) reflex. It is performed by stroking one of four abdominal quadrants in succession. The umbilicus should move towards the quadrant that was stroked. The reflex should be symmetrical from side to side. Absent or asymmetrical abdominal reflexes may indicate intraspinal pathology such as syringomyelia or spinal cord injury.

Myelopathy or UMN lesions are reported by spasticity, motor weakness, hyper-reflexia, positive Hoffmann's sign (forced flexion of the distal phalanx of the middle finger results in flexion of the thumb and index finger), upgoing Babinski response and patellar and ankle clonus.

Summary box 37.2

UMN lesions are characterised by:

- Increased tone – spastic
- Hyper-reflexia
- Muscle spasms
- Motor weakness
- Disuse atrophy
- Positive Hoffmann's sign
- Ankle and patellar clonus
- Upgoing plantar response

Typical signs of radiculopathy (lower motor neurone [LMN] lesion) include sensory loss, motor weakness, flaccid paralysis, muscle atrophy, loss of reflexes and muscle fasciculation. The straight leg raise (SLR) test is performed with the patient in the supine position. The leg is elevated with the knee straight to increase tension along the L5 and S1 nerve roots. The test is positive if the leg elevation provokes radicular pain. The crossed SLR test is carried out by elevating the asymptomatic leg; if positive, this produces sciatic symptoms in the opposite leg. A positive test is associated with a herniated disc

William Adams, 1820–1900, described the forward bending test for scoliosis in 1865. His understanding of the nature of the rotational element of scoliosis was given by a postmortem examination he performed on an eminent surgeon and geologist, Gideon Mantell.
Paul Schober, 1865–1943, German physician.
Johann Hoffmann, 1857–1919, Professor of Neurology, Heidelberg, Germany.
Joseph Francis Felix Babinski, 1857–1932, neurologist, Hôpital de la Pitié, Paris, France.

TABLE 37.2 Neurological evaluation of the upper limb.

Neurological level	Motor	Sensation	Reflexes
C5	Deltoid	Lateral arm	Biceps (C5/6)
C6	Wrist extensors	Lateral forearm	Brachioradialis (C5/6)
C7	Triceps	Middle finger	Triceps (C7/8)
C8	Long finger flexors	Medial forearm	No reflex
T1	Interosseus muscles	Medial arm	No reflex

TABLE 37.3 Neurological evaluation of the lower limb.

Neurological level	Motor	Sensation	Reflexes
L2	Hip flexion	Anterior thigh, groin	No reflex
L3	Knee extension	Anterior and lateral thigh	Patellar (L3/4)
L4	Ankle dorsiflexion	Medial leg and foot	Patellar (L3/4)
L5	Extensor hallucis longus	Lateral leg and foot	No reflex
S1	Ankle plantarflexion	Lateral foot and little toe	Achilles (S1/2)

in 97% of patients. Lasègue's sign denotes radicular pain aggravated by ankle dorsiflexion.

The femoral nerve stretch test is performed with the patient in the prone position by extending the hip and flexing the knee. This creates tension on the L2, L3 and L4 nerve roots. The femoral nerve stretch test is considered positive if radicular pain occurs in the anterior thigh region during the test.

The examination should include, where appropriate, examination of the shoulder, hip, knee, sacroiliac joint and vascular system, as dual pathology is common in the ageing community.

In 1979, Waddell and colleagues (see ***Further reading***) developed and validated a series of signs and tests that have proved helpful in identifying individuals who are magnifying or exaggerating symptoms, possibly for secondary gain (***Table 37.4***)

TABLE 37.4 Non-organic physical signs in low back pain.

- **Tenderness**: superficial or non-anatomical
- **Simulation tests**: axial loading or rotation
- **Distraction tests**: variable straight leg raises
- **Regional disturbances**: non-anatomical sensory or motor loss
- **Over-reaction**: grimacing, muscle tremor, etc.

Summary box 37.3

LMN lesions are characterised by:

- Decreased tone – flaccid
- Hyporeflexia
- Denervation fasciculations
- Motor weakness
- Sensory loss
- Severe atrophy
- Downgoing plantar response

Red flags

After taking a history and examining the patient it is important to consider 'red flags' (***Table 37.5***), which allow diagnostic triage into those with serious pathology of the spine, such as CES, fractures, tumours and infection, and those without.

Non-spinal causes of back pain

Pain may arise from the spine, but non-spinal causes of pain must also be considered (***Table 37.6***).

INVESTIGATIONS

The most common diagnostic imaging tests used to evaluate spinal disorders include plain radiographs, computed tomography (CT), magnetic resonance imaging (MRI), CT myelography and isotope bone scanning. These investigations are extremely sensitive, but relatively non-specific. For example, at least one-third of asymptomatic patients have been noted to have 'abnormalities' on MRI scans. All investigations must therefore be carefully correlated with the clinical findings.

Plain radiographs

It is not appropriate to order spine radiographs for every patient presenting with neck or low back pain. Patients with red flag signs or symptoms and those who have not responded to conservative treatment require imaging, with most units in resource-rich countries utilising MRI (no radiation penalty) in this situation. Standing radiographs of the whole spine are important for the assessment of scoliosis. Radiographs cannot diagnose early-stage tumour or infection, because significant bone destruction (between 40% and 60% of bone mass) must occur before a radiographic abnormality is detected.

Charles Ernest Lasègue, 1816–1863, Professor of Medicine, University of Paris, and physician, La Salpêtrière, Paris, France

TABLE 37.5 'Red flags': serious conditions whose signs and symptoms can cause low back pain.

Condition	Signs and symptoms
Cauda equina syndrome	• Severe or progressive bilateral neurological deficit of the legs, such as major motor weakness with knee extension, ankle eversion or foot dorsiflexion
	• Recent-onset urinary retention (caused by bladder distension because the sensation of fullness is lost) and/or urinary incontinence or alteration of function (caused by loss of sensation when passing urine)
	• Recent-onset faecal incontinence (due to loss of sensation of rectal fullness)
	• Perianal or perineal sensory loss (saddle anaesthesia or paraesthesia)
	• Unexpected laxity of the anal sphincter
Spinal fracture	• Sudden onset of severe central spinal pain that is relieved by lying down
	• A history of major trauma (e.g. road traffic collision or fall from a height), minor trauma or just strenuous lifting in people with osteoporosis who take corticosteroids
	• Structural deformity of the spine such as a step from one vertebra to an adjacent vertebra
	• There may be point tenderness over a vertebral body
Cancer	• The person being 50 years of age or more
	• Gradual onset of symptoms
	• Severe unremitting pain that remains when the person is supine, aching night pain that prevents or disturbs sleep, pain aggravated by straining (for example, at stool or when coughing or sneezing) and thoracic pain
	• Localised spinal tenderness
	• No symptomatic improvement after 4–6 weeks of conservative low back pain therapy
	• Unexplained weight loss
	• Past history of cancer; breast, lung, gastrointestinal, prostate, renal and thyroid cancers are more likely to metastasise to the spine
Infection (such as discitis, vertebral osteomyelitis or spinal epidural abscess)	• Fever
	• Tuberculosis or recent urinary tract infection
	• Diabetes
	• History of intravenous drug use
	• HIV infection, use of immunosuppressants or where the person is otherwise immunocompromised

HIV, human immunodeficiency virus.

TABLE 37.6 Non-spinal causes of low back pain: referred pain.

- Respiratory, e.g. mesothelioma
- Vascular, e.g. abdominal aortic aneurysm
- Renal, e.g. pyelonephritis
- Gastrointestinal, e.g. peptic ulcer, pancreatitis
- Urogenital, e.g. testicular, ovarian or prostatic carcinoma

Computed tomography

This investigation is the best test for assessing bone anatomy. Three-dimensional reconstructions are often useful for the assessment of congenital spinal deformity. However, one should remember that a typical CT of the lumbar spine will expose the patient to an effective dose of 5–10 millisieverts (mSv), which would be equivalent to 2.5–5 years of natural background radiation; those who travel on 7-hour flights (0.05 mSv per 7-hour flight) would need to make 100–200 journeys in their lifetime to be exposed to the same effective dose.

Magnetic resonance imaging

This allows detailed visualisation of the spinal cord, thecal sac, epidural space, intervertebral discs, nerve roots, paraspinal soft tissues and bone marrow. It is contraindicated for patients with certain pacemakers and coronary stents, intracranial metal clips, metallic bodies in the eye, spinal cord stimulators and certain drug pumps.

Bone scintigraphy

Isotope bone scans are highly sensitive, but non-specific, tests that are useful for screening the skeletal system for metastatic disease, discitis or vertebral body osteomyelitis, or to assess the relative activity of bone lesions such as osteoid osteoma, osteoblastoma, defects in the pars interarticularis or a pseudarthrosis (incomplete fusion). In the case of multiple myeloma or purely lytic metastases, the bone scan may not show increased activity as these tumours may not stimulate a significant **osteoblastic** response.

Figure 37.1 Lumbar discography. Antero-posterior (a) and lateral (b) radiographs following injection of contrast medium into the lower three lumbar discs. Morphology: L3/4 cotton ball, L4/5 fissured, L5/S1 ruptured. Concordant low back pain was reproduced when injecting the L4/5 and L5/S1 discs. No pain was experienced when the L3/4 disc was injected. The patient underwent a postero-lateral fusion L4 to S1.

Bone densitometry

Bone density and osteoporosis can be measured using dual energy x-ray absorptiometry (DEXA) of the hip, wrist and spine.

Provocative discography

This investigation involves the placement of a 24-gauge needle into the centre of the intervertebral disc in a conscious patient. Radio-opaque contrast agent (1–3.5 mL) is then injected into the disc. The contrast pattern will allow the discrimination of different degrees of disc degeneration; cotton ball or lobular would be considered normal whereas irregular, fissured or ruptured would be considered degenerate (*Figure 37.1*). The patient is asked if they are experiencing their 'usual type of back pain'. To diagnose discogenic low back pain one must document evidence of disc degeneration and concordant pain during the injection. Treatment options may include spinal fusion or disc replacement.

Facet joint injections

For patients with facet joint arthropathy, x-ray-guided local anaesthetic and steroid injections may be both diagnostic and therapeutic for 4–6 weeks. Longer term relief may be obtained by facet joint rhizolysis. This percutaneous procedure denervates the facet joint.

Foraminal epidural steroid injections

For patients with radiculopathy due to a prolapsed intervertebral disc or lateral recess stenosis, a targeted foraminal epidural injection of local anaesthetic and steroid may provide important diagnostic information and have a lasting therapeutic effect.

Spinal biopsy

Either CT-guided or open biopsy is often performed to obtain tissue for diagnostic study in cases of suspected tumour and/or infection.

DEGENERATIVE CONDITIONS OF THE SPINE

Cervical radiculopathy

Patients present with neck and arm pain (brachialgia), paraesthesia and motor weakness in the distribution of the compromised nerve root (radiculopathy). This may be caused by disc herniation or degenerative stenosis. Symptoms often respond to conservative treatment, including physiotherapy and medication for neuropathic pain (amitriptyline, gabapentin or pregabalin), or CT-guided foraminal epidural steroid injections of local anaesthetic and steroid. Intractable pain and/or functional neurological deficit are indications for surgical intervention. Surgical options include anterior cervical discectomy and fusion (using a cage packed with bone graft and plate), cervical total disc replacement (*Figure 37.2*) or posterior procedures to enlarge the canal such as laminoplasty and laminoforaminotomy. Randomised controlled trials have compared anterior cervical discectomy and fusion with cervical disc replacement. Similar clinical outcomes have been observed in both groups. However, cervical disc replacements preserve motion in the operated level and may protect against adjacent segment disease in the longer term.

Cervical myelopathy

Degenerative change in the cervical spine leading to spinal cord compression is the commonest cause of cervical myelopathy in patients over 55 years of age. LMN changes occur **at the level** of the lesion, with atrophy of the upper extremity muscles, particularly the intrinsic muscles of the hands. UMN findings are noted **below** the level of the lesion and may involve both upper and lower extremities. If surgery is considered an anterior or posterior decompression may be required.

Thoracic disc herniation

Thoracic disc herniations that require surgical intervention are rare, accounting for less than 2% of all discectomy procedures.

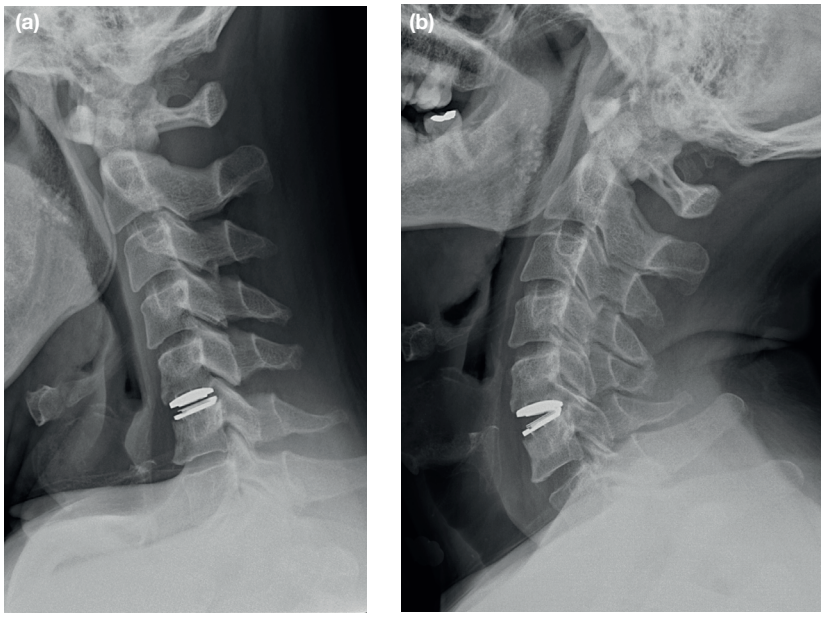

Figure 37.2 Cervical total disc replacement. The patient presented with severe left-sided C6 radiculopathy. Magnetic resonance imaging scan confirmed a left C5/6 disc herniation. The patient underwent a C5/6 discectomy and decompression of the left traversing C6 nerve root, followed by insertion of a cervical disc replacement. Lateral radiographs in flexion **(a)** and extension **(b)** show restored motion to the C5/6 level.

Typically, the patient presents with axial pain, radiculopathy or myelopathy. Conservative treatment including non-steroidal anti-inflammatory drugs, physiotherapy and general fitness improvement should be considered initially. If required, thoracic discectomy may be performed via thoracotomy or, for a soft disc prolapse, via a thoracoscopic approach.

Cauda equina syndrome

CES is a very serious and urgent condition that arises from compression of the cauda equina nerve roots, which supply the perineum and genital regions and bladder, bowel and sexual function. The most frequent cause is a massive central lumbar disc protrusion at L4/5 or L5/S1; other causes include lumbar fractures, postoperative epidural haematoma, spinal stenosis and spinal tumours. Occlusion of the lumbar arteries by dissection or aneurysm of the abdominal aorta can lead to similar dysfunction of the cauda equina without compression.

CES is rare, accounting for only 2–6% of all lumbar disc herniations. However, it is important as timely treatment can prevent catastrophic incontinence; delay in treatment is a major cause of litigation in many countries.

CES presents most commonly in the 20- to 45-year age group, with some or all of the following symptoms: low back pain; unilateral or bilateral sciatica; lower limb motor weakness; and sensory abnormalities, including saddle anaesthesia, bladder dysfunction (initially sensory changes, later painless retention and overflow incontinence in later stages) and sexual and bowel dysfunction. CES may result from acute or chronic compression of the cauda equina nerve roots.

TABLE 37.7 Classification of cauda equina syndrome (CES).

Name	Abbreviation	Definition	Investigation after initial diagnosis	Treatment if MRI positive for compression of CES
CES suspected	CES-S	Large disc herniation or bilateral sciatica but normal S2–5 motor and sensory function	MRI within 24 hours	Discuss risks and benefits of surgery versus conservative treatment
CES early	CES-E	Some perineal sensory change but normal bladder and bowel function	MRI immediate	Urgent decompression
CES incomplete	CES-I	Impaired bladder function or sensation but executive/voluntary control of bladder maintained	MRI immediate	Urgent decompression
CES retention	CES-R	Bladder retention and overflow incontinence	MRI immediate	Urgent decompression on next daytime list if patient presents overnight
CES complete	CES-C	Complete loss of cauda equina function	MRI in working hours	Decompression if improvement considered possible

MRI, magnetic resonance imaging.

Cauda equina nerve roots lack epineurium and perineurium and only have a thin endoneurium root sheath, making them more susceptible to compression forces when compared with peripheral nerves. The syndrome can result in permanent motor deficit and bladder, bowel and sexual dysfunction. It represents a true spinal emergency and requires urgent surgical decompression. The outcome for patients who undergo surgical decompression within 24 hours of the onset of loss of bladder or bowel control is significantly better than that of those who undergo surgery beyond this 24-hour period.

Cauda equina syndrome classification

The key classification of CES (*Table 37.7*) is into cases where there is still executive or voluntary control of the bladder (CES-I) and cases where there is bladder retention and overflow incontinence (CES-R). CES-I cases are considered to be more urgently in need of decompression to prevent deterioration to CES-R. Most surgeons now believe that continued compression causes a continuous deterioration in function and therefore early decompression is of benefit.

Summary box 37.4

Cauda equina syndrome

- Commonest presenting symptoms: perineal numbness, alteration in bladder function and sensation leading to painless urinary retention, overflow incontinence and faecal incontinence
- Urgent investigation with MRI is required for all suspected cases
- Confirmed CES requires surgical decompression within 24 hours to achieve optimum outcomes

Lumbar disc herniation

Symptomatic lumbar disc herniation occurs during the lifetime in approximately 2–4% of the population. Risk factors include family history, male gender, age (30–50 years), heavy lifting or twisting, stressful occupation, lower income and cigarette smoking.

Over 90% of lumbar disc herniations occur at the L4/5 or L5/S1 levels. A posterolateral disc protrusion will affect the **traversing** root, e.g. an L4/5 disc protrusion will affect the L5 nerve root. A far-lateral disc protrusion (extraforaminal) will affect the **exiting** nerve root, e.g. a far-lateral L5/S1 disc protrusion will affect the L5 nerve root. Symptoms typically commence with a period of back pain followed by sciatica. There may be paraesthesia, motor weakness, loss of reflexes and a reduction in SLR.

For simple sciatica, a period of 6–12 weeks of conservative treatment is advised. Up to 70% of patients will settle within this period. A trial of pregabalin (GABA analogue) and/or a transforaminal epidural steroid injection may be helpful. Microdiscectomy is the standard surgical intervention for those in whom conservative treatment has failed. The procedure is carried out in the prone position with radiographic confirmation of the correct level. Loupes with a headlight or use of the operating microscope greatly facilitate the procedure. A 3- to 4-cm incision is made with a unilateral take down of the multifidus. The spinal canal is entered via removal of the ligamentum flavum under the lamina. The thecal sac and traversing nerve root are identified. The dura and nerve root are retracted medially and the offending disc prolapse incised via a transverse annulotomy. The disc fragment is removed and the disc space cleared of any remaining nuclear material with rongeurs and multiple washouts of the disc space. The wound is closed. Patients are generally discharged the next morning.

Spinal stenosis

Spinal stenosis may be defined as any type of narrowing of the spinal canal, nerve root canal or intervertebral foramen. The resultant nerve root compression leads to nerve root ischaemia, presenting with back, buttock or leg pain provoked by exercise. Spinal stenosis may be congenital, as is the case in achondroplasia, or acquired, as is the case for degenerative types (commonly presenting between 50 and 70 years of age). The narrowing is caused by facet joint hypertrophy, disc bulging and ligamentum flavum thickening.

Symptoms of spinal claudication can be distinguished from vascular claudication because they are frequently associated with neurological symptoms, are often worse in extension and pedal pulses are present on clinical examination. Symptoms progress in approximately 20–33% of patients who receive no treatment. The condition may be treated successfully by surgical decompression alone with preservation of the facet joints.

Summary box 37.5

Spinal stenosis

- Extremely common condition in the 50- to 70-year age group
- Classic symptoms: back, buttock, thigh and calf pain
- Provoked by walking and extended posture
- Relieved by flexed posture
- Symptoms progress in up to one-third of untreated patients

Discogenic low back pain

Discogenic low back pain has been defined as a continuum of diagnostic categories (internal disc disruption, degenerative disc disease, segmental instability) reflecting various stages of degenerative pathology affecting the intervertebral disc. Not all degenerate discs are painful. Patients typically present with chronic relapsing episodes of low back pain between the ages of 40 and 60 years.

A recent study has compared rehabilitation with spinal fusion for discogenic pain. Both groups reported reductions in disability, with the authors strongly recommending a course of rehabilitation **before** surgical intervention. For those who fail to improve with conservative measures, provocative lumbar discography (*Figure 37.1*) may help to identify the source of pain, and surgery in the form of a lumbar spinal fusion (*Figure 37.3*) or lumbar disc replacement (*Figure 37.4*) may be considered.

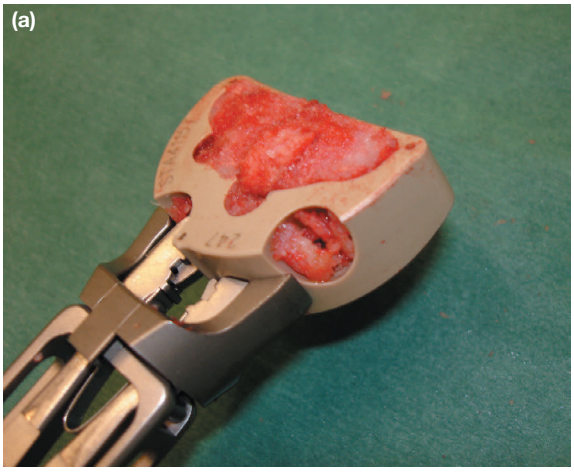

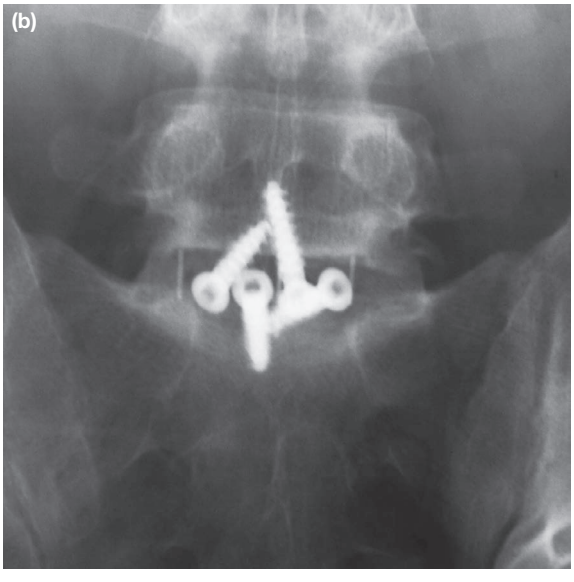

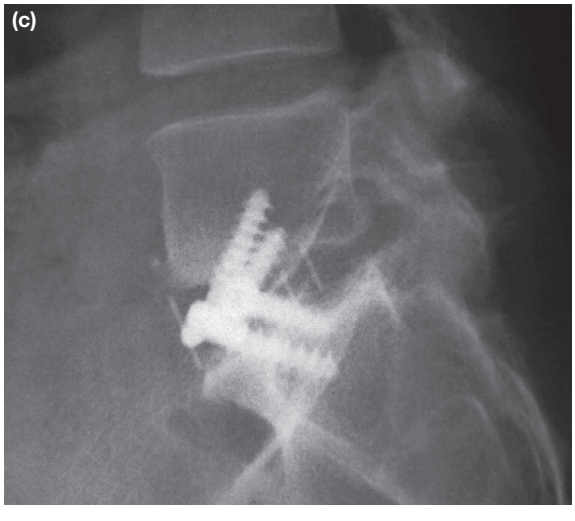

Figure 37.3 Anterior lumbar interbody fusion. **(a)** The PEEK (poly-ethyl-ethyl-ketone) cage has been packed with bone graft prior to insertion; **(b, c)** show the anteroposterior and lateral postoperative radiographs, respectively.

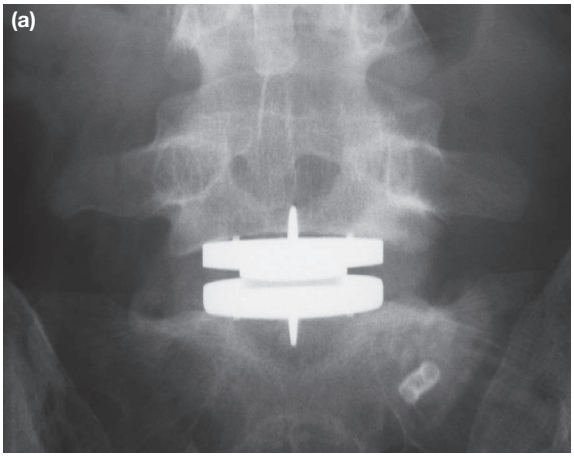

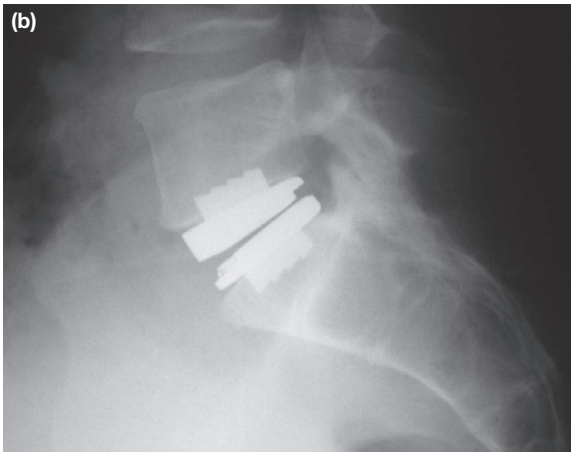

Figure 37.4 Lumbar total disc replacement. **(a)** Anteroposterior radiograph with 30° of cranial inclination. **(b)** Lateral radiograph with the implant appropriately positioned.

SPONDYLOLYSIS AND SPONDYLOLISTHESIS

Spondylolysis

This is a unilateral or bilateral defect in the pars interarticularis without vertebral slippage. The incidence is reported in approximately 6% by the age of 14 years, but is much higher in the young athletic population. The diagnosis is difficult to confirm with plain radiographs. Reverse gantry CT, MRI and single photon emission computed tomography (SPECT) are useful investigations for this condition. Treatment involves rest, non-steroidal anti-inflammatory medication, activity modification and a lumbosacral orthosis. For patients who remain symptomatic despite an adequate trial of non-operative care, surgery in the form of a direct repair of the pseudarthrosis by a Buck's fusion may be indicated.

J E Buck, surgeon, Brook General Hospital, London, UK, described the direct repair of the defect in spondylolisthesis in 1970.

Summary box 37.6

Spondylolysis

- Incidence in general population 6% by 14 years
- Incidence in athletic population 15–47%
- May be completely asymptomatic/incidental finding on radiograph
- Difficult to image, but MRI proving more useful
- Conservative treatment: activity modification, anti-lordotic brace
- Surgical treatment: direct repair preserving motion or spinal fusion if associated disc degeneration

Spondylolisthesis

Spondylolisthesis is a forward slippage of the vertebral body engendered by a break in the continuity or elongation of the pars interarticularis and presents in 4% of the adult population. Spondylolisthesis can be classified into six types by causation (*Table 37.8*) or by the degree of slip (*Table 37.9*).

For skeletally immature patients (<18 years old) who have progressive slips in the spine, and in individuals with intractable low back or radicular pain or neurological symptoms, surgery may be indicated. For low-grade slips (Meyerding grades I and II) fusion-*in-situ* is the procedure of choice. If there is **objective** evidence of neural compression (e.g. weakness of extensor hallucis longus), a spinal decompression should be performed at the same time. For high-grade slips (Meyerding grades III or IV) (*Figure 37.5*), opinion is divided on whether to reduce the slip first and then fuse, or simply to fuse *in situ*.

TABLE 37.8 Wiltse classification of spondylolisthesis (see *Further reading*).

Type 1	Dysplastic	• Associated with congenital deficiency of the L5/S1 articulation

Type 2	Isthmic	• Associated with a lesion of the pars interarticularis
		• Three subtypes:
		  ◦ 2A: lytic defect of the pars
		  ◦ 2B: elongated or attenuated pars
		  ◦ 2C: acute pars fracture

Type 3	Degenerative spondylolisthesis	• Segmental instability due to disc degeneration/facet arthrosis
Type 4	Traumatic	• Acute fracture in the region of the posterior elements, other than the pars interarticularis
Type 5	Pathological	• Generalised bone disease resulting in attenuation of the pars (e.g. metabolic, neoplastic)
Type 6	Post surgical	• After decompression of the lumbar spine

TABLE 37.9 The Meyerding classification for the degree of slip of spondylolisthesis.

Grade I	1–25%
Grade II	26–50%
Grade III	51–75%
Grade IV	76–100%

TUMOURS OF THE SPINE

Metastatic tumours

The commonest malignancies that metastasise to the spine are shown in *Table 37.10*. Red flags picked up on history or examination will alert the clinician to this possible diagnosis.

Over 80% of patients with spinal metastases present with progressive pain, and only 20% present with spinal cord compression. Relevant investigations include full blood count (FBC), urea and electrolytes, liver function tests, calcium, erythrocyte sedimentation rate (ESR), C-reactive protein (CRP), prostate-specific antigen (PSA), serum protein electrophoresis, thyroid function tests (where a thyroid mass has been palpated) and nutritional indices. Plain radiographs may show an absent pedicle ('winking owl' sign), vertebral cortical erosion and/or vertebral collapse. MRI of the whole spine will detect most metastases. Most metastases are **osteoblastic** and will show up on bone scintigraphy; however, **osteolytic** lesions such as multiple myeloma and renal cell carcinoma may not show up on an isotope bone scan. Metastases from the prostate may be sclerotic. Biopsies may be obtained via a percutaneous CT-guided method or open biopsy.

TABLE 37.10 Commonest malignancies that metastasise to the spine and their frequency.

Breast	21%
Lung	14%
Prostate	7.5%
Renal	5%
Gastrointestinal	5%
Thyroid	2.5%

Treatment options include orthotics, steroids (dexamethasone), radiotherapy, chemotherapy, hormonal therapy, surgery or a combination of any of the above. Radiotherapy promotes reossification of the vertebral body and reduces tumour load. It can be very effective for reducing 'bone pain'. Lymphoma, breast, lung and prostate metastases are **highly radiosensitive**. Gastrointestinal adenocarcinoma, metastatic melanoma, thyroid and renal carcinoma are **radioresistant**. Small cell carcinoma of the lung, Ewing's sarcoma, thyroid carcinoma, breast carcinoma and neuroblastoma are usually sensitive to chemotherapy and should have chemotherapeutic agents as the first-line management. Adenocarcinoma of the lung is resistant to chemotherapy. Prostate metastases may respond well to antiandrogenic hormone medication.

Henry W Meyerding, 1884–1969, Professor of Orthopaedic Surgery, Mayo Clinic, Rochester, MN, USA.
James Ewing, 1866–1943, Professor of Pathology, Cornell University Medical College, New York, NY, USA, described this type of sarcoma in 1921.

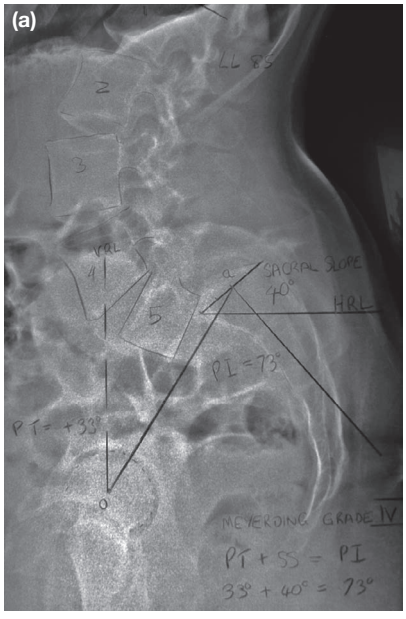

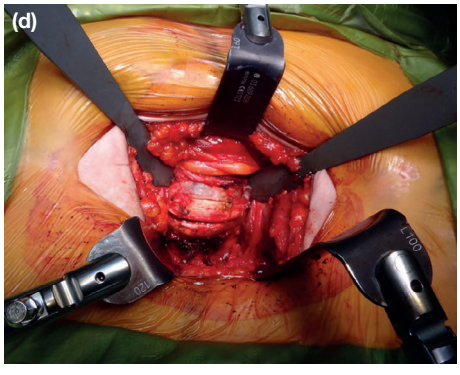

Figure 37.5 High-grade spondylolisthesis. Lateral standing radiograph **(a)** demonstrates Meyerding grade IV slip associated with high pelvic incidence. Anteroposterior (AP) radiograph **(b)** demonstrates the inverted Napoleon hat sign. T2-weighted mid-sagittal magnetic resonance imaging scan **(c)** shows the 'domed sacrum'. The patient underwent a modified Gaines procedure under one anaesthetic **(d)** with anterior vertebral resection of L5 along with the L4/5 and L5/S1 intervertebral discs, followed by resection of the posterior elements, articular process and L5 pedicles. AP **(e)** and lateral **(f)** radiographs demonstrate final reduction of L4 onto the sacrum with pedicle fixation from L4 to S2. **(g)** Postoperative full-length lateral standing radiograph at 12 months.

Robert W Gaines Jr, contemporary, surgeon, Department of Orthopaedic Surgery, University of Missouri, Columbia, MO, USA.

Extensive reconstructive tumour surgery should be reserved for those patients whose life expectancy exceeds 3–6 months. For patients with malignant spinal cord compression, the combination of decompressive surgery with stabilisation and postoperative radiotherapy has been shown to be superior in outcome when compared with radiotherapy alone. In one randomised trial, surgery and radiotherapy permitted most patients to remain ambulatory for the remainder of their lives, whereas patients treated with radiotherapy alone spent a large portion of their remaining time as paraplegics.

Summary box 37.7

Metastatic tumours of the spine

- Commonest presentation is progressive spinal pain
- Whole-spine MRI will detect most metastases
- Surgery is indicated for instability, pain, progressive deformity or neurological deficit

Primary tumours of the spine

Primary bone tumours of the spine account for only 2% of all spinal tumours. They arise *de novo* in the bone, cartilage, neural or ligamentous structures of the spine. They may be benign, intermediate or malignant. Benign primary spine tumours include osteoid osteoma, osteoblastoma (***Figure 37.6***), chondroma, chondroblastoma, chondromyxoid fibroma, giant cell tumours, haemangioma, lymphangioma and lipoma. Intermediate primary spine tumours include aggressive osteoblastoma, haemangiopericytoma, haemangioendothelioma and chordoma. Malignant primary spinal tumours include osteosarcoma, chondrosarcoma, Ewing's sarcoma, neuroectodermal tumours, malignant lymphoma, myeloma, angiosarcoma, fibrosarcoma and liposarcoma. The reader is

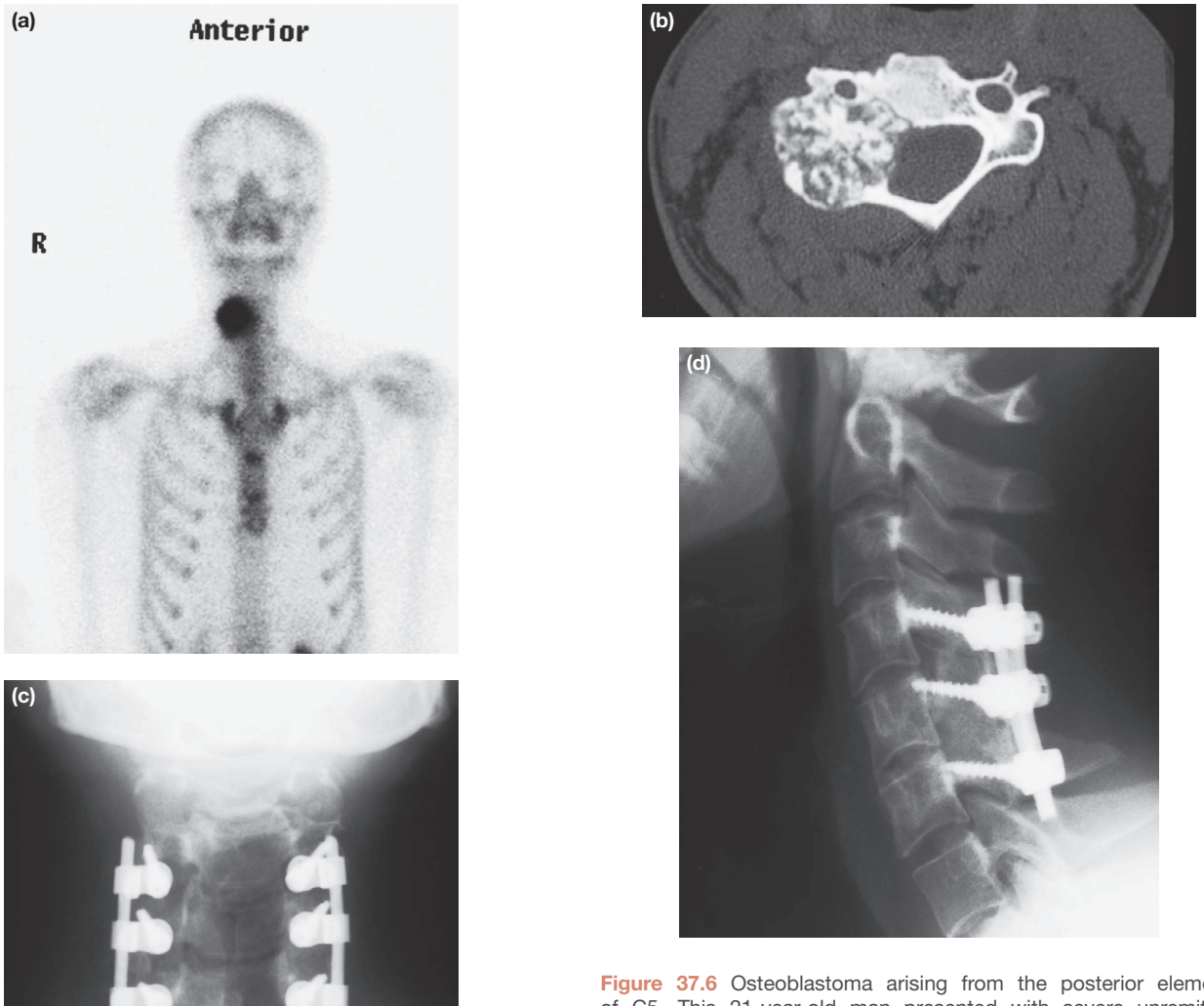

Figure 37.6 Osteoblastoma arising from the posterior elements of C5. This 21-year-old man presented with severe unremitting neck pain. Isotope bone scan **(a)** demonstrated increased uptake in C5. An axial computed tomography scan **(b)** further delineated the expansive lesion. The tumour was successfully removed with the aid of an intraoperative gamma probe to confirm complete excision; **(c, d)** postoperative anteroposterior and lateral radiographs, respectively, following reconstruction with a tricortical bone graft, lateral mass screws and rods.

referred to *Chapter 42* for further information on orthopaedic oncology.

In patients less than 18 years of age, 68% of all tumours are benign. For those patients who present over 18 years of age, more than 80% of tumours are malignant. Benign tumours tend to occur in the posterior elements; malignant tumours tend to involve the vertebral body.

Intradural tumours

These are rare. They may be intramedullary (within the substance of the spinal cord) or extramedullary (outside the cord). Most are extramedullary and benign; the commonest are meningiomas and neurofibromas.

Meningiomas are usually benign and arise from the meninges. They are generally slow growing and often warrant radiological surveillance. If the lesion is large and impinges on the spinal cord or nerve roots, steroids and early surgery may be indicated.

Neurofibromas are benign tumours that arise from the nerve sheath. There are three major types of neurofibroma: cutaneous, spinal and plexiform. In 90% of cases they present as solitary lesions, with the remainder presenting in patients with neurofibromatosis type 1 (NF-1), an autosomal dominant genetically inherited disease. NF-1 occurs in 1 in 3000 births and has been referred to as peripheral neurofibromatosis or von Recklinghausen disease. Diagnosis of NF-1 is confirmed when an individual has two or more of the following: at least six café-au-lait macules >5 mm diameter before puberty or six café-au-lait macules >15 mm after puberty, two or more neurofibromas of any type or one plexiform neurofibroma, multiple freckles in the axillary or inguinal regions, a distinctive bone abnormality involving the eye socket or arm/leg bones, optic glioma in the brain, two or more Lisch nodules in the eye, and a parent, sibling or child with NF-1. Neurofibromatosis type 2 (NF-2) is a genetically determined disorder that affects 1 in 40 000 individuals worldwide. A diagnosis of NF-2 is made when an individual has the following findings: schwannomas on both eighth cranial (vestibular) nerves or a parent, sibling or child with NF-2 plus one vestibular schwannoma in a person less than 30 years of age, or any two of the following: meningioma, glioma, schwannoma, juvenile cataracts.

INFECTIONS OF THE SPINE

Pyogenic infections

Pyogenic vertebral osteomyelitis is primarily a lesion of the disc and its osseous margins. The most common method by which an organism spreads to the spine is via the haematogenous route. The disc is nearly always involved in pyogenic vertebral infection. In contrast, granulomatous infection, such as tuberculosis, typically does not involve the disc space.

Risk factors for pyogenic vertebral osteomyelitis include advancing age, intravenous drug abuse, diabetes, renal failure, recent infections and trauma. *Staphylococcus aureus* accounts for 30–55% of the infections. Gram-negative organisms such as *Escherichia coli*, *Pseudomonas* species and *Proteus* species are associated with recent genitourinary infections and intravenous drug abuse. Anaerobic infections are uncommon, but may be seen in diabetic patients and after penetrating trauma.

If there is a failure of medical management (persistent pain, elevated erythrocyte sedimentation rate, C-reactive protein), operative interventions that should be considered are shown in *Table 37.11*.

TABLE 37.11 Operative interventions in pyogenic infections that should be used from a surgical perspective.

- Open biopsy (when a closed biopsy has failed)
- Drainage of abscesses
- Decompression of spinal cord compression
- Correction of progressive spinal deformity
- Stabilisation of progressive spinal instability

Epidural abscess

This condition is often a surgical emergency. The majority of cases occur within the thoracic spine. Without treatment, neurological deficit, including paralysis, may develop.

Tuberculosis

This is discussed in *Chapters 6 and 43*.

INFLAMMATORY SPONDYLOARTHROPATHY

Rheumatoid arthritis

Disease-modifying anti-rheumatic drugs (DMARDs) are a class of drugs indicated for the treatment of rheumatoid arthritis. Conventional medications have been used such as methotrexate, leflunomide, hydroxychloroquine and sulfasalazine. Newer biological agents are now available, including infliximab, adalimumab and etanercept. These medications have improved the outcomes significantly.

Between 33% and 50% of patients develop atlantoaxial subluxation (AAS) within 5 years of the diagnosis of rheumatoid arthritis. Some 2–10% of patients with AAS develop myelopathy over the next 10 years. Once diagnosed with myelopathy, 50% of patients may die within 1 year. The degree of subluxation may need to be checked by performing flexion and extension radiographs, and the theatre staff (especially the anaesthetist) need to be warned to take special care especially with intubation. The indications for surgery to stabilise the cervical spine are given in *Table 37.12*.

Friedrich Daniel von Recklinghausen, 1833–1910, Professor of Pathology, Strasbourg, France, described generalised neurofibromatosis in 1882.
Karl Lisch, 1907–1999, ophthalmologist, Wörgl, Austria.
Friedrich Theodor Schwann, 1810–1882, Professor of Anatomy successively at Louvain (1839–1848) and Liège, Belgium (1849–1880).
Hans Christian Joachim Gram, 1853–1938, Professor of Pharmacology (1891–1900) and of Medicine (1900–1923), Copenhagen, Denmark, described this method of staining bacteria in 1884.
Theodor Escherich, 1857–1911, Professor of Paediatrics, Vienna, Austria, discovered the *Bacterium coli commune* in 1886.

TABLE 37.12 Recommendations for spinal surgery in rheumatoid arthritis.

- AAS with a PADI of 14 mm or less
- AAS with at least 5 mm of basilar invagination
- Subaxial subluxation with a sagittal canal diameter of 14 mm or less

AAS, atlantoaxial subluxation; PADI, posterior atlantodental interval.

Ankylosing spondylitis

Should a patient with ankylosing spondylitis present following trauma, a high index of suspicion for occult fractures should be present. It is common for patients with ankylosing spondylitis to develop epidural haematomas with subtle neurological deficit.

Patients with a significant fixed flexion deformity at the cervicothoracic junction ('chin-on-chest' deformity), limited forward gaze and eating and swallowing difficulties may be treated with a closing wedge osteotomy at the cervicothoracic junction (*Figure 37.7*). Extension osteotomies can also be performed in the thoracic and lumbar spine.

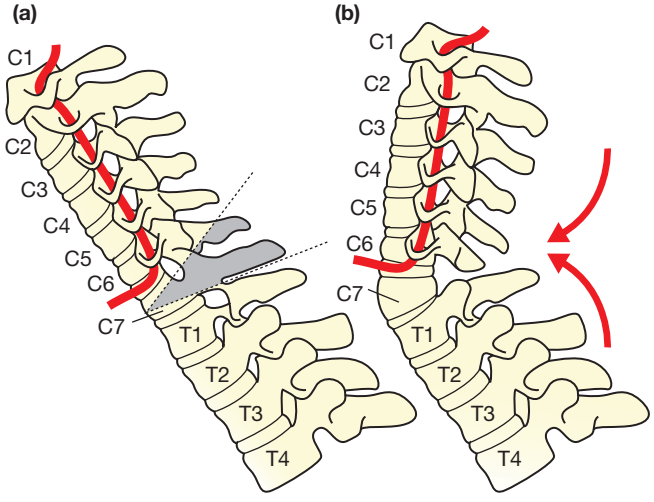

Figure 37.7 C7 closing wedge osteotomy for correction of cervicothoracic kyphosis in patients with ankylosing spondylitis. Planned resection lateral view **(a)** and lateral view after closure of the osteotomy **(b)**.

SPINAL DEFORMITY

Spinal deformity may be categorised into a coronal plane deformity (scoliosis) or a sagittal plane deformity (kyphosis and lordosis). Further classification may be made on the basis of aetiology into congenital, neuromuscular, idiopathic or syndromic. Appropriate radiographs for the assessment of scoliosis include a full posteroanterior and lateral standing spine. When surgery is contemplated, supine lateral bending radiographs are obtained to assess the flexibility of the curve(s). Curve magnitude is measured in degrees and is known as the Cobb angle. The criterion for diagnosis of scoliosis is a Cobb angle of 10° or more. The causes of scoliosis are given in *Table 37.13*.

TABLE 37.13 Aetiology of scoliosis.

- Idiopathic
- Neuromuscular
- Congenital
- Syndrome-related

Idiopathic scoliosis

Idiopathic scoliosis accounts for 70% of presentations. It can be classified into **early onset** (before 8 years of age) (*Figure 37.8*) and **late onset** (after 8 years of age; typical adolescent idiopathic scoliosis). The distinction is important, as the number of alveoli in the lung does not increase after the age of 8 years. Patients with severe curves in the early-onset group may develop cor pulmonale and right ventricular failure resulting in premature death. Adolescent idiopathic scoliosis is associated with a normal or near-normal life expectancy.

The prevalence of curves with a Cobb angle >10° is between 0.5% and 3%. The prevalence of curves >30° is between 1.5 and 3 per 1000. Risk factors for progression include female gender, remaining skeletal growth, curve location and curve magnitude. Not all curves stabilise when skeletal maturity is reached. In long-term studies, 68% experienced curve progression; the most marked progression of 1° per year was observed in patients with thoracic curves between 50° and 75°.

Idiopathic curves of less than 25° are monitored with clinical and radiographic examination. In growing children (premenarchal) with curves between 20° and 29°, a brace may be indicated. Bracing is used to **prevent** curve progression and generally does not lead to permanent curve correction. Curves beyond 45° are not amenable to brace treatment.

Surgery in the form of corrective instrumentation and spinal fusion is indicated for curve progression beyond 40°, truncal imbalance and unacceptable cosmesis. During surgery, continuous spinal cord monitoring is used in the form of somatosensory evoked potentials (SSEPs), motor-evoked potentials (MEPs) and free-run and stimulated electromyographic (EMG) activity to minimise the risk of neurological damage. The risk of neurological injury is 0.4% (1 in 250).

Neuromuscular scoliosis

This may be due to neuropathic disorders, such as cerebral palsy, spinocerebellar degeneration, syringomyelia, tetraplegia (*Figure 37.9*), spinal muscular atrophy and poliomyelitis, or **myopathic** disorders, such as Duchenne muscular dystrophy and myotonic dystrophy. There is good evidence that stabilisation of the spine in children with Duchenne muscular dystrophy who are able to walk (before respiratory compromise is too severe to preclude a general anaesthetic) may increase their lifespan by several years.

John R Cobb, American surgeon, wrote a paper in 1948 on how to measure the angle on a radiograph in scoliosis.
Guillaume Benjamin Amand Duchenne, 1806–1875, neurologist, worked successively in Boulogne and Paris, France, but never held a hospital appointment.

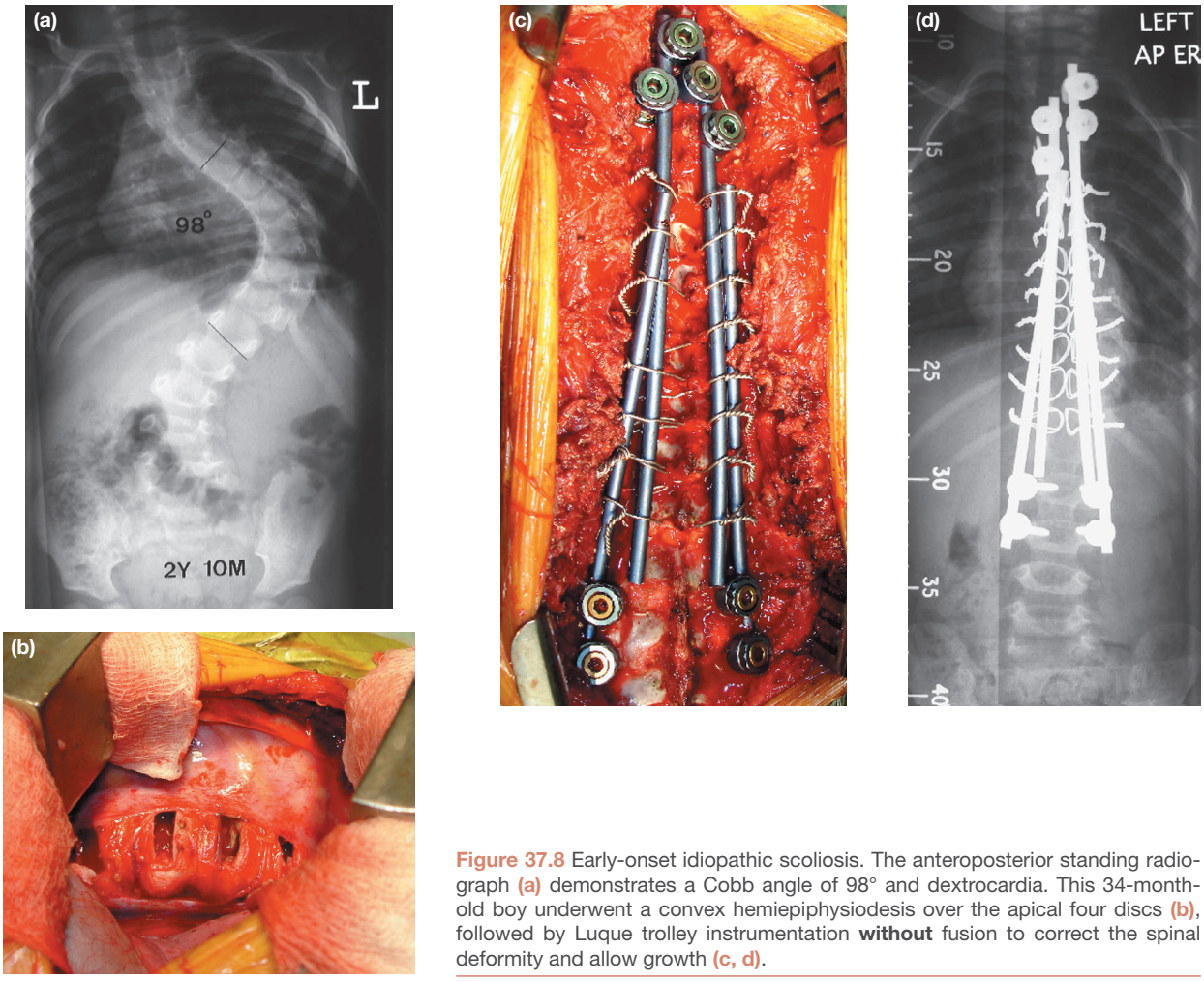

Figure 37.8 Early-onset idiopathic scoliosis. The anteroposterior standing radiograph **(a)** demonstrates a Cobb angle of 98° and dextrocardia. This 34-month-old boy underwent a convex hemiepiphysiodesis over the apical four discs **(b)**, followed by Luque trolley instrumentation **without** fusion to correct the spinal deformity and allow growth **(c, d)**.

Congenital scoliosis

This is caused by vertebral anomalies that produce a frontal plane growth asymmetry. The anomalies are present at birth, but the curvature may take years to be clinically evident. Close observation of spinal growth is required until skeletal maturity is reached. Brace treatment is ineffective for the primary structural curves, which are often short and rigid, but it may have a role in the control of compensatory curves. For progressive curves, surgical options include growing rod constructs such as magnetically controlled growing rod procedures, hemivertebra excision, correction and fusion or posterior instrumented correction and fusion.

Summary box 37.8

Spinal deformity

- Early-onset idiopathic scoliosis (<8 years old) has the potential to impair lung function
- Neuromuscular scoliosis: timely surgery may prolong life
- Congenital scoliosis: rigid curves do not respond to brace treatment

Scheuermann's kyphosis

Typically, in this condition, there is wedging of the seventh to 10th thoracic vertebrae. The patient presents with both apical pain and low back pain (due to attempts by the lumbar musculature to compensate for the thoracic hyperkyphosis). The incidence has been estimated at 1–8% of the population, and it is more common in males. Physiotherapy may be useful. Bracing for skeletally immature patients with kyphosis up to 65° may be effective in arresting progression. Indications for surgery include pain (apical or low back pain produced by compensatory hyperlordosis), progressive deformity greater than 70°, unacceptable cosmesis and neurological and/or cardiopulmonary compromise. If surgery is contemplated, it may require anterior release followed by posterior correction and fusion. Increasingly, posterior chevron osteotomies carried out at the time of posterior instrumentation may prevent the need for the initial anterior release.

DEVELOPMENTAL ABNORMALITIES

Developmental abnormalities of the spine and spinal cord can be divided into primary bony disorders (e.g. congenital

Eduardo Luque, contemporary, professor, Shriners Hospital for Crippled Children, Mexico City, Mexico.
Holger Werfel Scheuermann, 1877–1960, radiologist, Municipal Hospital, Sundby, Copenhagen, Denmark, described juvenile kyphosis in 1920.

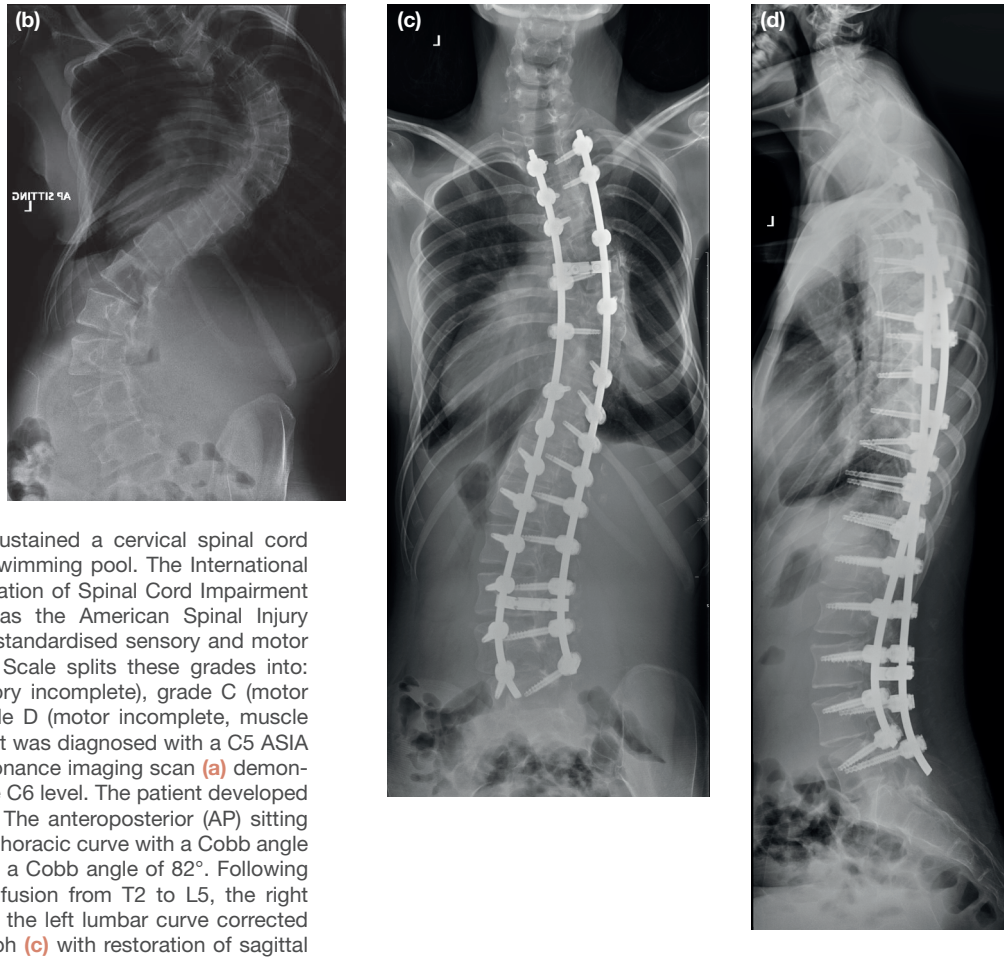

Figure 37.9 This 13-year-old girl sustained a cervical spinal cord injury (SCI) following a dive into a swimming pool. The International Standards for Neurological Classification of Spinal Cord Impairment (ISNCSCI), commonly referred to as the American Spinal Injury Association (ASIA), are based on a standardised sensory and motor assessment. The ASIA Impairment Scale splits these grades into: grade A (complete), grade B (sensory incomplete), grade C (motor incomplete, muscle grade <3), grade D (motor incomplete, muscle >3) and grade E (normal). The patient was diagnosed with a C5 ASIA B SCI. The T2 sagittal magnetic resonance imaging scan (a) demonstrated signal change maximal at the C6 level. The patient developed significant neuromuscular scoliosis. The anteroposterior (AP) sitting radiograph (b) demonstrates a right thoracic curve with a Cobb angle of 104° and a left lumbar curve with a Cobb angle of 82°. Following pedicle screw instrumentation and fusion from T2 to L5, the right thoracic curve corrected to 40° and the left lumbar curve corrected to 38° as noted on the AP radiograph (c) with restoration of sagittal balance (d).

scoliosis, as discussed above) and primary neurological disorders (e.g. spina bifida, Arnold–Chiari malformation and spinal dysraphism).

Spina bifida

Spina bifida is caused by a failure of fusion of the vertebral arches and possibly the underlying neural tube. Spina bifida cystica has an incidence of 1 in 300 live births and is associated with hydrocephalus. It is now decreasing as a consequence of folic acid supplementation, antenatal ultrasound and the measurement of α-fetoprotein (AFP) levels. There are two basic types:

- **Meningocele**: the meninges herniate through the bony defect and are covered by skin.
- **Myelomeningocele**: the roof of the defect is formed by exposed neural tissue, with 75% of patients developing hydrocephalus.

A meningocele with good-quality skin over the defect may be treated conservatively. A meningocele with a more prominent sac can be excised at 3–6 months. The management of myelomeningocele is more controversial. Enthusiasm for closing all defects has been replaced by a more selective approach with the recognition that it was inappropriate to operate on children with severe hydrocephalus, a large open defect and no distal neurological function. The majority of these children die in their first year if closure is not attempted. With antibiotics, early surgical closure and shunts to prevent hydrocephalus, half the children who survive the first 24 hours will reach school age, but long-term problems remain, including skin problems, neuromuscular scoliosis, bone and joint deformity and the complications associated with a neuropathic bladder.

Arnold–Chiari malformation

Arnold–Chiari malformation occurs when the medulla oblongata and the cerebellar tonsils extend through the foramen magnum into the cervical spinal canal, causing pressure on the lower medulla. Hydrocephalus and impaired neurological function are common, and there is a strong association

Julius Arnold, 1835–1915, Professor of Pathological Anatomy, University of Heidelberg, Heidelberg, Germany, described this condition in 1894.
Hans Chiari, 1851–1916, Professor of Pathological Anatomy, Strasbourg, Germany (Strasbourg was returned to France in 1918 after the end of the First World War), gave his account of this condition in 1891.

with spina bifida and syringomyelia. Symptoms may include headache, vomiting, visual disturbances, mental impairment, cerebellar ataxia, sensory disturbances or paralysis. Management consists of decompressing the foramen magnum and, usually, the posterior arch of the atlas to restore normal cerebrospinal fluid flow.

Spinal dysraphism

This is a group of disorders arising from abnormal embryological formation of tissues; all are associated with a progressive neurological deficit as the result of spinal cord tethering and traction or cord compression. There is a strong association with spina bifida.

In diastematomyelia, there is an abnormal bony or cartilaginous spur projecting across the middle of the vertebral canal, dividing the dural tube and spinal cord in two. Between 50% and 70% of patients are seen to have a skin naevus, dimple or hairy patch when the spine is examined. Surgical release of the tethering has variable results.

Syringomyelia

Patients may present with sensory disturbance, weakness of the hands, loss of pain and temperature sensation, asymmetrical abdominal reflexes or progressive kyphoscoliosis. It is associated with Arnold–Chiari malformation and spinal cord tumours. Where syringomyelia is associated with an Arnold–Chiari malformation and scoliosis, a posterior cranial fossa decompression should be carried out first to resolve the syringomyelia. The scoliosis may then be corrected at a later date.

METABOLIC BONE DISEASES AFFECTING THE SPINE

Osteoporosis

Patients with osteoporosis may present with pain following minimal trauma, loss of height and exaggerated thoracic kyphosis. Medications used to prevent and treat osteoporosis include calcium, vitamin D, bisphosphonates (alendronate, risedronate, once-yearly intravenous zoledronic acid), denosumab, strontium ranelate, selective oestrogen receptor modulators (SERMs) such as raloxifene, hormone replacement therapy and teriparatide.

Patients with painful thoracic fractures may be treated with short-term bed rest, analgesics and a spinal orthosis. If the back is still painful 6 weeks after the injury, patients may be considered for vertebroplasty or kyphoplasty. Vertebroplasty involves the injection of polymethylmethacrylate (PMMA) bone cement under pressure into the vertebral body with fluoroscopic guidance. The goals of the procedure are to **stabilise the spine** and **decrease the pain** associated with compression fractures. Kyphoplasty, on the other hand, involves inserting bilateral bone tamps with balloons into the vertebral body. These are inflated under fluoroscopic control with the bone tamp re-expanding the body, and elevating the end plates to reduce the fracture deformity. The balloons are then deflated and removed, and PMMA is placed in the cavity created by the balloons. The goals of kyphoplasty are **spinal stabilisation, pain relief and restoration of vertebral body height**. Significant complications have been reported, including nerve root injury and spinal cord injury resulting from cement extravasation, along with cement embolism, infection and hypotension.

GLOBAL ISSUES IN SPINE SURGERY

It is important that the information presented in this chapter, which is widely used throughout the world for teaching and training, outlines the very best evidence-based treatment that is available for surgical conditions. The text has covered the essentials of spine surgery and has very rightly demonstrated current techniques that involve up-to-date equipment. It is, however, an inescapable fact that the majority of the world's population does not have access to state-of-the-art spinal surgery. There are two main reasons for this: first, the cost of spinal surgery and, second, the lack of trained surgeons.

Cost implications of modern spinal surgery

There have been dramatic advances in spinal surgery owing to modern imaging, modern instruments and implants, and advanced spinal cord monitoring equipment. The widespread availability of MRI in high-income countries such as the USA, the UK and most of Europe has meant that diagnostic accuracy is available to the whole population in these countries. This is not, however, the case for most of the world, where there is no free or state-sponsored MRI service, and a private scan costing US$500 is unaffordable to most. If a family cannot afford a scan, then they also cannot afford the cost of an operation, the spinal implants, spinal cord monitoring and the use of expensive disposable instruments such as high-speed burrs.

The lack of trained spinal surgeons

In the last 25 years high-income countries have seen the rapid development of spinal surgery, and the rapid development of spinal surgery as a complete career. It is now normal in such countries for spinal surgeons to practise only in the field of spinal surgery and no longer to undertake general orthopaedic or neurosurgical operations. This has inevitably led to refinement of skills and increasing subspecialisation. In low-income countries, where there may be a single orthopaedic surgeon for 1 million people, doing 'just spinal surgery' is not an option, and a much more general approach is needed. In the map shown in *Figure 37.10*, each country in the world is represented with an area proportional to the number of people in the population per active surgeon. This represents surgeons of all types, but it shows that, in many parts of Africa, there are more than half a million people per surgeon. The map showing the population covered by each **spinal** surgeon would be even more striking.

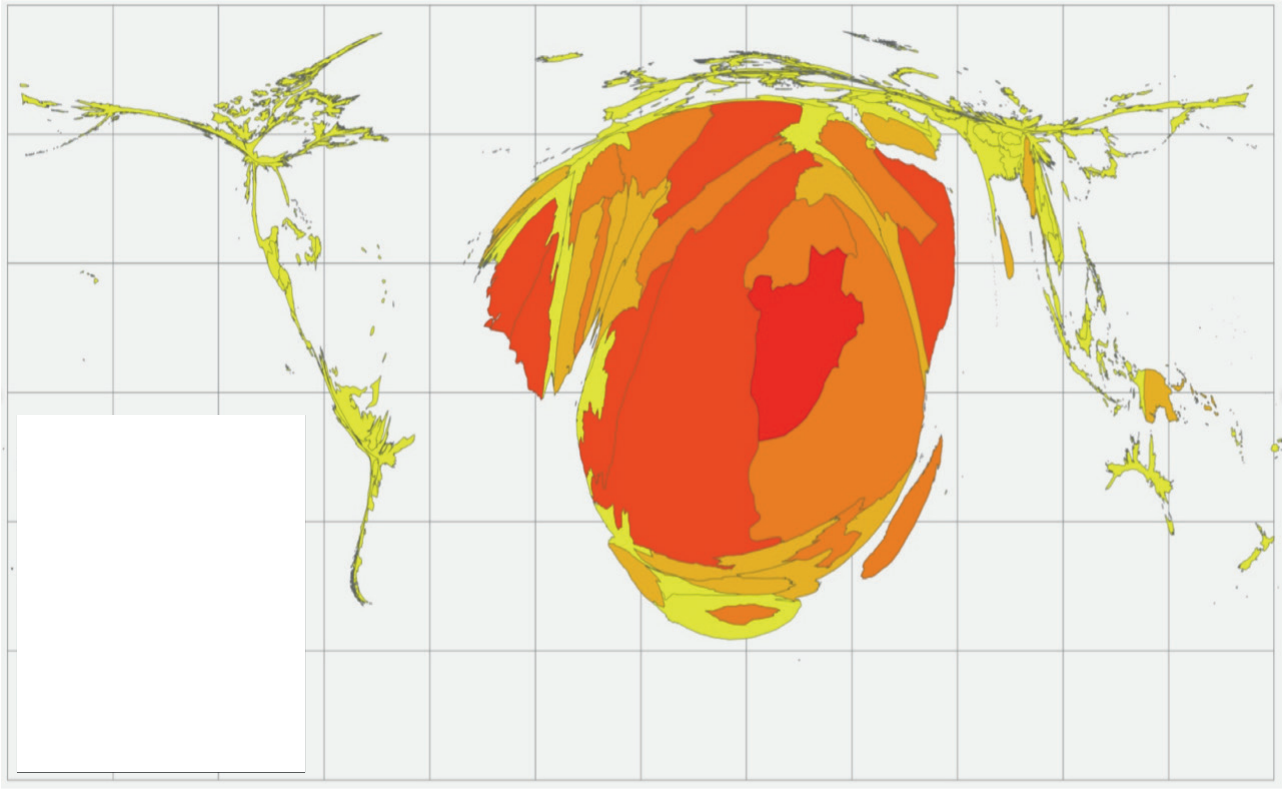

Figure 37.10 Global distribution of surgeons, anaesthetists and obstetricians. Each country in the world is represented with an area proportional to the number of the population per active surgeon. (Reproduced with permission from Holmer H, Lantz A, Kunjumen T *et al*. Global distribution of surgeons, anaesthesiologists, and obstetricians. *Lancet Glob Health* 2015; **3**(Suppl 2): S9–11.)

Figure 37.11 (a) Lateral cervical spine radiograph with a fracture/dislocation at C2/3 sustained by a patient living in a low-income country. (b) The surgeon used a low-risk, low-technology technique, wiring the arch of C1 to the spine of C2 with a piece of stainless steel wire, then laying on corticocancellous bone graft.

Can good spine care be given without modern imaging and equipment?

The key to good surgery in all disciplines is a surgeon who is dedicated to the care of his or her patient, who takes a good history and examination and then offers the best treatment that is available under the circumstances. In a high-income country this will often involve MRI scanning, dissection under microscope control and expensive titanium implants. In a resource-poor, low-income country it may involve just as much time and skill, but often a much more conservative approach. When surgery is needed the surgeon may have to do the best that he or she can with the equipment available. The case in ***Figure 37.11*** illustrates this point well. Note the lateral cervical spine radiograph with a fracture/dislocation at C2/3 sustained by a patient living in a low-income country. The pedicles of C2 are fractured, allowing C2 to subluxate forwards on C3 and compress the spinal cord. The patient was admitted several days after a car crash, holding his head with his hands for stability. In a high-income country where there is imaging and fluoroscopic-guided pedicle screw fixation, the fracture could easily be fixed. In the low-income country, there was no cervical spine instrumentation available and the surgeon used a low-risk, low-technology technique of wiring the arch of C1 to the spine of C2 with stainless steel wire, then laying on corticocancellous bone graft. The reduction was stable, the graft incorporated and the patient was thankful. It is not appropriate to say that this was inadequate treatment compared with the best that the world has to offer, because the best that the world has to offer was not available.

FURTHER READING

Debnath UK, Freeman BJ, Gregory P *et al.* Clinical outcome and return to sport after the surgical treatment of spondylolysis in young athletes. *J Bone Joint Surg Br* 2003; **85**(2): 244–9.

Fairbank J, Frost H, Wilson-McDonald J *et al.* Randomised controlled trial to compare surgical stabilisation of the lumbar spine with an intensive rehabilitation programme for patients with chronic low back pain: the MRC spine stabilisation trial. *BMJ* 2005; **330**: 1233–8.

Fritzell P, Hägg O, Wessperg P *et al.* Volvo Award in Clinical Science: lumbar fusion versus non-surgical treatment for chronic low back pain. A multi-centre randomised controlled trial from the Swedish Lumbar Spine Study Group. *Spine* 2001; **26**: 2521–34.

Gardner A, Gardner E, Morley T. Cauda equina syndrome: a review of the current clinical and medico-legal position. *Eur Spine J* 2011; **20**(5): 690–7.

Holmer H, Lantz A, Kunjuman T *et al.* Global distribution of surgeons, anaesthesiologists, and obstetricians. *Lancet Glob Health* 2015; **3**: S9–11.

Janssen ME, Zigler JE, Spivak JE *et al.* ProDisc-C total disc replacement versus anterior cervical discectomy and fusion for single-level symptomatic cervical disc disease. Seven-year follow-up of the prospective randomized U.S. Food and Drug Administration investigational device exemption study. *J Bone Joint Surg Am* 2015; **97**(21): 1738–47.

Meara JG, Leather AJ, Hagander L *et al.* Global Surgery 2030: evidence and solutions for achieving health, welfare, and economic development. *Lancet* 2015; **386**: 569–624.

Patchell RA, Tibb PA, Regine WF *et al.* Direct decompressive surgical resection in the treatment of spinal cord compression caused by metastatic cancer: a randomised trial. *Lancet* 2005; **366**: 643–8.

Srikandarajah N, Noble A, Clark S, *et al.* Cauda Equina Syndrome Core Outcome Set (CESCOS): an international patient and healthcare professional consensus for research studies. *PLoS ONE* 2020; **15**(1): e0225907.

Tokala DP, Lam KS, Freeman BJ *et al.* C7 decancellisation closing wedge osteotomy for the correction of fixed cervico-thoracic kyphosis. *Eur Spine J* 2007; **16**(9): 1471–8.

Waddell G, McCulloch JA, Kummel ED *et al.* Volvo Award in Clinical Science: non organic physical signs in low-back pain. *Spine* 1979; **5**: 117–25.

Wiltse LL, Newman PH, Macnab I. Classification of spondylosis and spondylolisthesis. *Clin Orthop* 1976; **117**: 23–9.